

SCARF OSTEOTOMY

HALLUX VALGUS

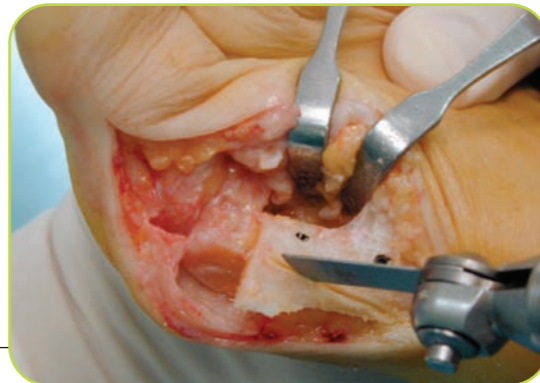Document produced by the TALUS group of GECO (www.geco-medical.org) - 2004.



ASSOCIATED ACTS

It is usually necessary to resect the projecting bony edge of the upper part of the metatarsal. The bone fragment thus released can be repositioned on the lateral edge of the metatarsal.

Release of the abductor tendon of the great toe can be performed at this stage or later during closure.



Resection of the bony margin after scarf osteotomy

VERIFICATIONS AND TESTING

The corrections must be stable before capsular closure. It is important to ensure the quality of the reduction and the stability of the procedure at this stage by simulating weight bearing. If the cartilaginous surface is properly positioned and tension imbalance corrected, it is reasonable to expect a satisfactory long term result.

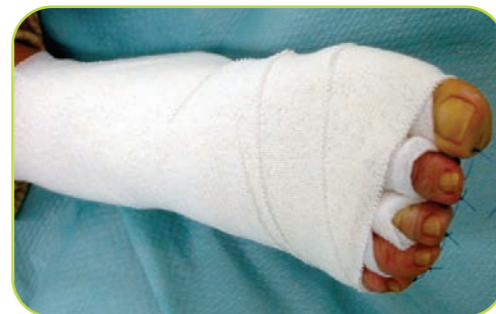CLOSURE

The surgeon closes in his usual manner. However it is essential that the capsular plane be sutured (absorbable sutures suffice in our experience) prior to closure of the superficial planes.

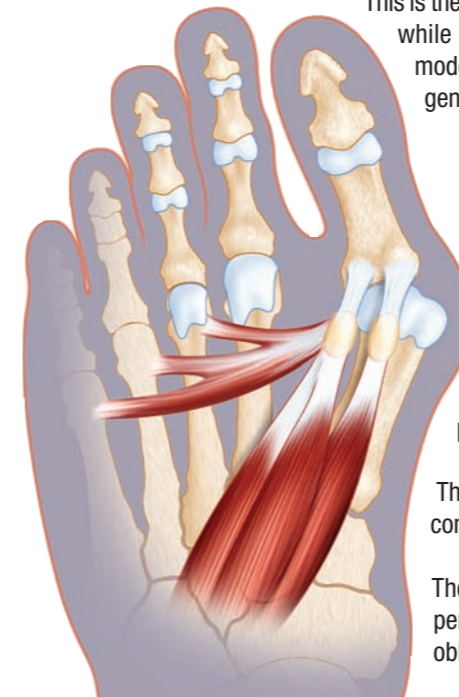
According to surgeon preference, the tourniquet can be released to attain haemostasis prior to closure. Drain and suture the subcutaneous plane then using either continuous or interrupted sutures close the skin. Nonabsorbable stitches are removed after 2 to 3 weeks.

POSTOPERATIVE CARE

- > Usually there is no need to replace the dressing. If applied carefully, taking correction of the deformities into account, the dressing from the operating theatre can be left in place for about fifteen days.
- > It is advisable to administer prophylactic anticoagulation.
- > It is advisable for the patient to wear a special postoperative shoe for a period of between a fortnight to a month.



Dressings



This is the most familiar technique used in France as it allows translation of the 1st MT head while permitting rotation and shortening. It is the gold standard and is ideal for moderate Hallux Valgus in women aged over 50 years. The fixation obtained is generally extremely stable.

MEDIAL INCISION AND SOFT TISSUE RELEASE

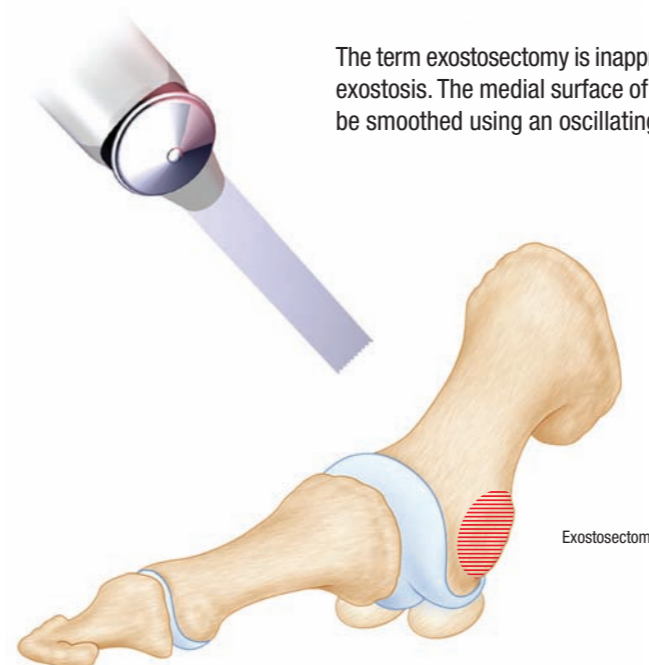
The usual incision is straight or omega-shaped and made at the junction of the plantar and dorsal skin. A medial capsular approach and lateral arthrolysis are possible through a single incision.

The joint can be sufficiently well released to mobilise the distal segment without compromising blood supply to the head.

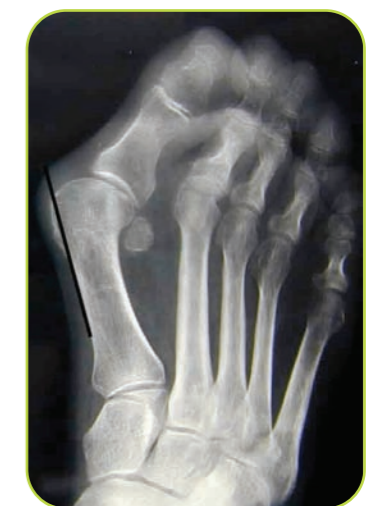The aim is to release and mobilise the mal positioned sesamoids. This approach permits section of the metatarsosesamoid ligament and release of the direct and oblique tendons of the adductor hallucis.

EXOSTOSECTOMY

The term exostosectomy is inappropriate as this is really an irregularity rather than a true bony exostosis. The medial surface of the 1st MT head is, however, irregular. Irregularities should be smoothed using an oscillating saw or nibblers (Gouge forceps).



Exostosectomy



Radiograph showing the osteotomy line for resurfacing

Document subsidized by:

USA, **FH**ORTHOPEDICS INC

909 THIRD AVENUE, SUITE 500 - NEW YORK, NEW YORK 10022 - TEL.: 646 495 3112 - FAX: 646 495 3113 - fsanti4651@aol.com



OTHERS, **FH**ORTHOPEDICS S.A.S

Rue de la Forêt - 68990 HEIMSBRUNN (FRANCE) - TEL. : +33 3 89 81 90 92 - FAX : +33 3 89 81 80 11 - orthopedie@f-h.fr / www.f-h.fr

Creation: transparence en France - www.transparence.com - 03/2005

METATARSAL OSTEOTOMY

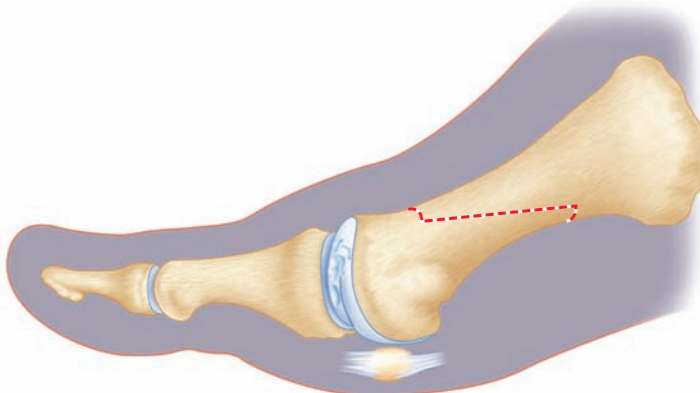
Use an oscillating saw. The principle is to isolate the metatarsal head now angulated towards the body from the baguette-shaped diaphyseal plantar segment. The lines can be variously oriented according to surgeon preference. The osteotomies should allow lateralisation of the distal segment so that head and sesamoids are repositioned.

The fact that the plane of the cut runs obliquely in the frontal plane and parallel to the inferior surface of the metatarsal enables the 1st MT head to be lowered in order to restore weight bearing to the first ray.

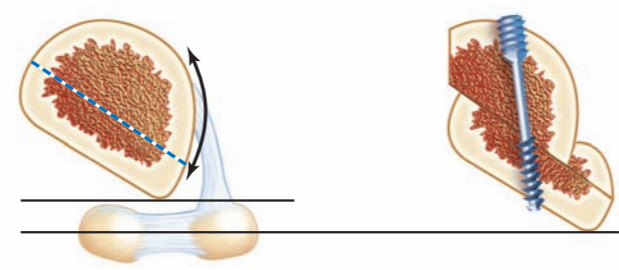
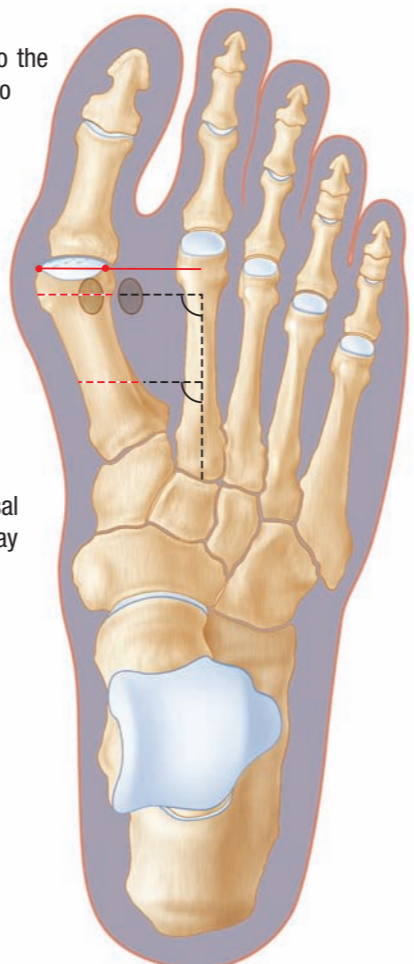
The main cut, which runs obliquely outward, downward and backward, begins 2 mm under the first MT neck and ends 2 mm above the plantar cortical bone at the metaphyseal junction of the 1st MT. It can be made shorter or longer according to surgeon preference or to the reduction desired.

Secondary resections can be used to obtain shortening or rotation.

It is often necessary to resect the proximal, lateral corner of the translated metatarsal fragment in order to avoid contact with the medial cortical bone of the 2nd MT, which may prevent the desired reduction.



Lateral view of a scarf osteotomy



FIXATION

Once the correction has been obtained the bone fragments are stabilised using the special clamp. Using the special drill, distal drilling is performed either vertically, which brings about bicortical purchase, or angled towards the metatarsal head to ensure a good grip in cancellous bone. The lengths required are read directly from the gauge.

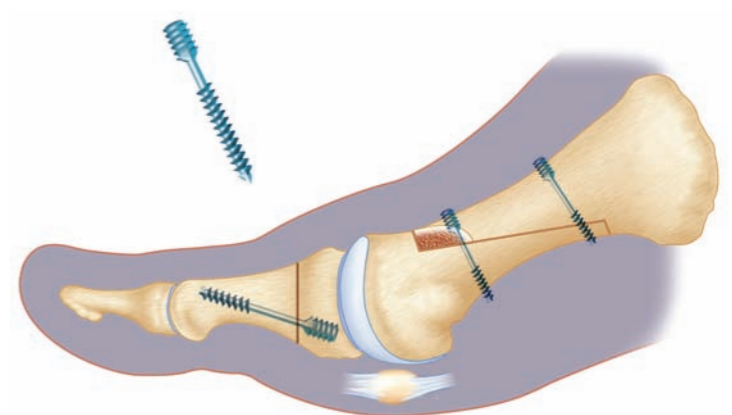
The length of the self-compressing screw is selected in accordance with one of the following options:

- > For cortical bone purchase the length is taken exactly as read or one size up e.g. (13 mm reading => 14 mm screw).
- > For cancellous bone the screw length should be shorter to avoid the screw penetrating the joint.

The screw is supplied sterile. It is positioned manually by holding it using the grip. The surgeon should not touch the implant itself.

The separation of implant and gripping device will occur early and more or less so according to bone quality. The surgeon then uses the screwdriver to complete the positioning of the screw. It is important to ensure that the hex head of the screwdriver is properly engaged with the screw to avoid any damage to the screw head.

The second screw is inserted in position using the same technique aiming for bicortical purchase.



Scarf and phalangeal osteotomy with fixation by self-compressing screw

L10	242 446	L24	247 581
L12	242 447	L26	242 451
L14	242 448	L28	242 452
L16	242 449	L30	242 453
L18	242 450	L32	242 454
L20	247 579	L34	242 455
L22	247 580	Ref. FH ORTHOPEDICS	

SNAP-OFF SELF-COMPRESSING SCREW

