

POST OPERATIVE MANAGEMENT & REHABILITATION

Based on our current knowledge of tendon healing, the post-surgical period can be divided into 4 successive phases. The success of the percutaneous tenosynthesis depends on these 4 phases being respected.

D 1 to D 21 PRIMARY CALLUS FORMATION PHASE

- Splint immobilisation :
 - in the equinus position in a removable orthosis,
 - with no weight-bearing.
- Start rehabilitation (optional) :
 - gentle mobilisation,
 - less than 90°,
 - painless.

D 21 to D 45 CONNECTIVE HEALING PHASE

- Phase promoted by weight-bearing and mobilisation.
- Immobilisation in removable splint :
 - at 90°,
 - start assisted weight bearing.
- Rehabilitation by daily mobilisation of the ankle :
 - passive and assisted active for plantar flexion,
 - active for dorsal flexion.

D 45 +/- 7 days REMOVAL

- Removal of the TENOLIG on D45 :
 - by sectioning through the threads under the buttons,
 - outpatient procedure,
 - careful disinfection,
 - local anaesthetic on the proximal incisions to allow the harpoon to be pulled out painlessly (optional).

D 45 to D 90 CALLUS MATURATION PHASE

- Recovery of the tendon's physical properties.
- Total weight-bearing in shoes :
 - plantar orthosis with raised protective heelpiece,
 - gradually decrease the height.
- Proprioceptive rehabilitation of the lower limb :
 - recovery of joint movement range,
 - gradually build up the triceps muscle.
- Gradually increase physical activities : swimming, cycling, etc.
- No jumping on one foot.

Warning : high-risk period for recurrent rupture !

D 90 to D 120 DEFINITIVE HEALING PHASE

- Total weight bearing in shoes, without plantar orthosis.
- Continued recovery of the triceps.
- Gradual resumption of sports activities (D90) and competitive activities (D120).
- Sport permitted : running.

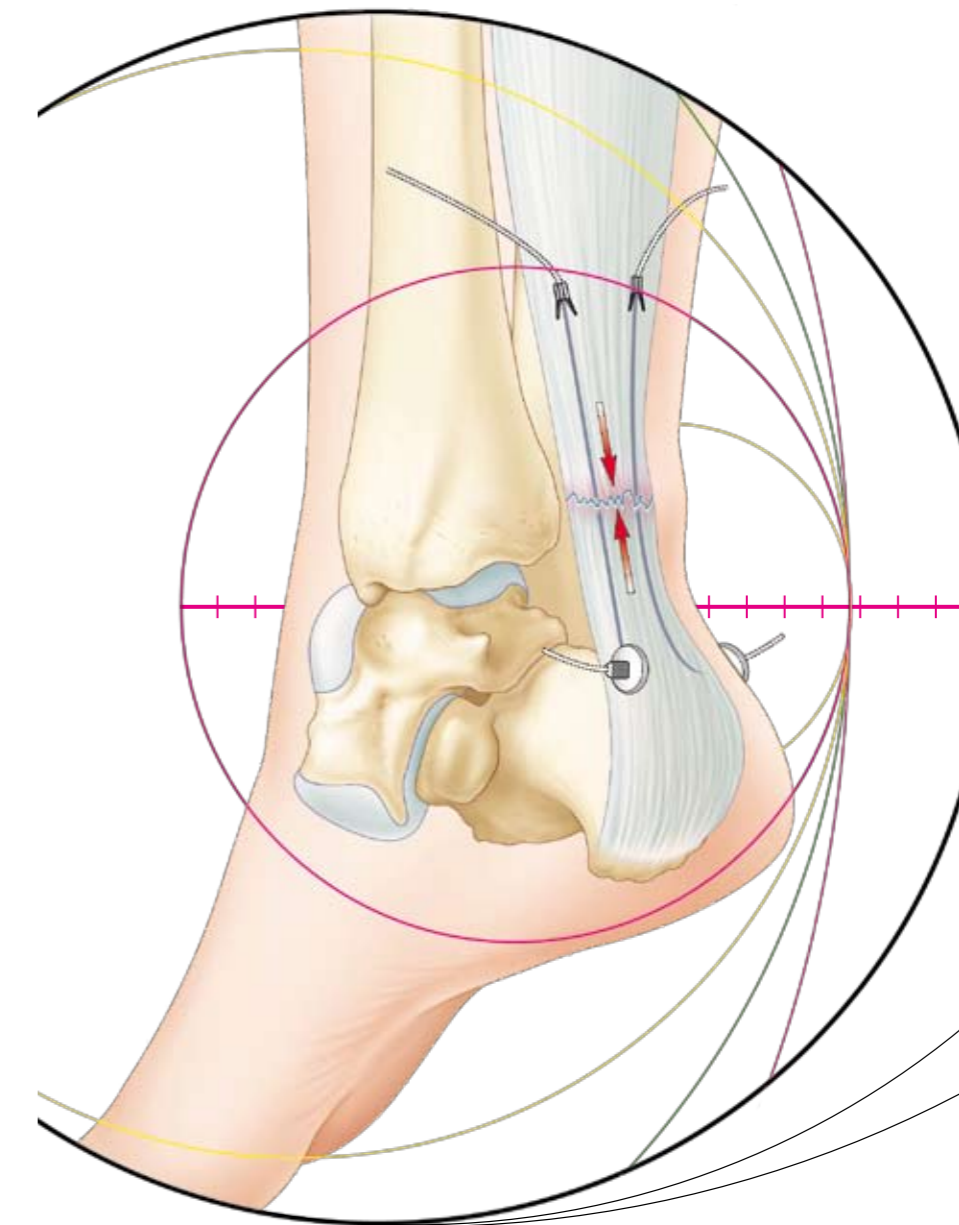
Preventing of thrombo-embolic complications by anticoagulants until a resumption of total weight-bearing.

PRODUCT REFERENCE : 232 942
(BATCH OF 2) TENOLIG™ IMPLANT for PERCUTANEOUS TENOSYNTHESIS
FDA approved



REFERENCES

1. ALDAM C.H.: Repair of calcaneal tendon ruptures. A safe technique. J. Bone Joint Surg. 1989, 71-B, 486-488.
2. BESCH S., ROLLAND E, KHIAMI F. Rupture récente et ancienne du tendon calcanéen chez l'adulte. Journal de traumatologie du sport, juin 2008, pages 114-115.
3. BRADLEY J. TIBONE J. Percutaneous and open surgical repairs of Achilles tendon ruptures. A comparative study. Am. J. Sports Med., 1990, 18, 188-195.
4. BUISSON P., BATISSE J., POTIER L. et Coll. Traitement des ruptures du tendon d'Achille selon la technique de ténorrhaphie percutanée. J. Traumatol. Sport 1996, 13, 204-211.
5. COPIN G. et le Groupe TALUS. Notre expérience de la ténosynthèse percutanée des ruptures du tendon d'Achille. Med. Chir. Pied 1998, 14, 4, 192-197 et Communication aux journées tuniso françaises de podologie 29 et 30 mai 1998.
6. DIEBOLD PF., DELPONTE P, COILLARD JY. – le groupe TALUS. La ténorrhaphie percutanée dans les ruptures du tendon d'Achille. Communication lors des journées de printemps de l'association française de chirurgie du pied. Lyon, 7 et 8 mai 1999.
7. DELPONTE P. Le ténorrhaphie percutanée du tendon d'Achille. Maîtrise orthopédique, 1995, n°45
8. DELPONTE P, POTIER L., DE POULPIQUET P., BUISSON P. Traitement des ruptures sous cutanées du tendon d'Achille par ténorrhaphie percutanée. Rev. Chir. Orthop. 1992, 78, 404-407. Également publié dans The Journal of Orthopaedic Surgery, 1992, 6, N°4.
9. DELPONTE P. et le groupe Talus. Traitement des ruptures récentes du tendon calcanéen par voie percutanée. Med. Chir. Pied 1997, 13, 87-91.
10. FITZGIBBONS R.E., HEFFERON J., HILL J. Percutaneous Achilles tendon repair. Am. J. Sports Med. 1993, 21, 724-727.
11. GIGANTE A, MOSCHINI A, VERDENELLI A, DEL TORTO M, ULISSE S, DE PALMA L. Open versus percutaneous repair in the treatment of acute Achilles tendon rupture: a randomized prospective study. Knee Surg Sports Traumatol Arthrosc. 2008, 16, 204-209.
12. GUNEPIN FX., RONGIERAS F, CHAUVIN F, BOUQUET JP, ROMANET JP. Ténosynthèse percutanée du tendon calcanéen par TENOLIG : à propos de 30 cas. Communication lors des journées de printemps de l'association française de chirurgie du pied. Lyon, 7 et 8 mai 1999.
13. KAKIUCHI M. A combined open and percutaneous technique for repair of tendon Achilles. J. Bone Joint Surg. 1995, 77-B, 60-63.
14. KOUVALCHOUK J.F., RODINEAU J., WATIN-AUGOUARD L. Les ruptures du tendon d'Achille. Comparaison des résultats du traitement opératoire et non opératoire. Rev. Chir. Orthop. 1984, 70, 473-478.
15. KOUVALCHOUK J.F., MOUJTAHID M. Réflexions à propos du traitement des ruptures du tendon d'Achille par suture percutanée. J. Traumatol. Sport 1999, 16, 222-228.
16. LAFFENÈTRE O., CERMOLACCE C., COILLARD JY., DELAVIGNE C., DETERME P., DIEBOLD P., GUILLO S., PHILIPPE M. et le groupe TALUS, Tenolig et sport : étude prospective d'une série de 35 patients évalués par étude isocinétique et revus à un an de recul, juin 2004. Communication également effectuée lors d'une réunion de l'AFCP en septembre 2004. Lors du congrès d'Arcachon en 2004 et pour la SFMCP en décembre 2004
17. LEA R.B., SMITH L. Non surgical treatment of tendon Achilles rupture. J. Bone Joint Surg. 1972, 54-A, 1398-1407.
18. LECESTRE P. et la S.O.R. - Ruptures du tendon d'Achille traitées par ténorrhaphie percutanée, à propos de 100 cas. Ann. Orthop. Ouest, 1997, 29, 103-106 et European Journal of Orthopaedic Surgery and Traumatology, 1997, 7 : 37-40
19. MA G.W.C., GRIFFITH T.G. Percutaneous repair of acute closed ruptured Achilles tendon. A new technique. Clin. Orthop. 1977, 128, 247-255.
20. MARTINELLI B. Percutaneous repair of the Achilles Tendon in Athletes. Bulletin – Hospital for Joint Diseases. 59, 2000, N°3 : 149.
21. Mc GOMIS G.P., NAWOCZENSKI D.A., DE HAVEN K.E. Functional bracing for rupture of the Achilles tendon. J. Bone Joint Surg. 1997, 79-A, 1799-1808.
22. MERTL P. JARDE O., TRANVAN F., DOUTRELOT P., VIVES P. Ténorrhaphie percutanée pour rupture du tendon d'Achille. Rev. Chir. Orthop. 1999, 85-277-285.
23. THERMANN H., ZWIPP H., TSCHERNE H. Functional treatment concept of acute rupture of the Achilles tendon. 2 years results of a prospective randomized study. Unfallchir. 1995, 98, 21-32.
24. THIERY J.F., DROUIN C., DEMORTIERE E., de BELENET H. Traitement des ruptures du tendon d'Achille par ténorrhaphie percutanée et dynamisation immédiate. Communication au GECCO 2000



TENOLIG™
IMPLANT FOR PERCUTANEOUS
TENOSYNTHESIS OF THE
ACHILLES TENDON

www.fhorthopedics.com

ACHILLES TENDON RUPTURES

PERCUTANEOUS TENOSYNTHESIS

The usual therapeutic attitude of surgeons when they are faced with the problem of Achilles tendon ruptures varies between 2 possible solutions, depending on the case :

- pure orthopaedic treatment with immobilisation, or
- surgical repair (whether this involves straightforward suturing or a more complex repair). This is usually combined with strict immobilisation.

Histological and biological studies on tendon healing have made it possible to consider surgical repair by the **percutaneous** route, aimed at early and effective physiotherapy leading to a satisfactory result both with respect to solidity and to patient comfort.

Monitoring of the results obtained over more than 15 years has culminated in the technique that we now propose today.

Percutaneous tenosynthesis combines reliability, patient comfort and a reduction in the overall social and professional costs of this type of injury.

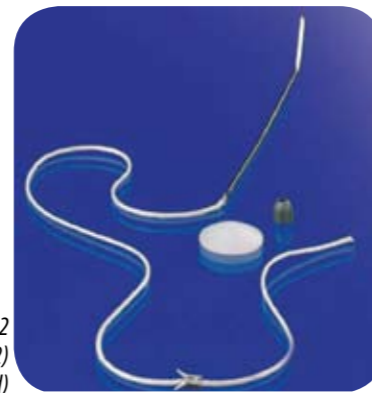
PRINCIPLES

- 1 To join together the two ruptured ends of the Achilles tendon without using a surgical approach, with this join being maintained **for more than 5 weeks**, at the same time permitting the **immediate mobilisation** of the tendon as a unit during flexion / extension movements of the foot.
- 2 **Not to devascularise the tendon** by opening up of its vascular sheath at an untimely moment.
- 3 To **preserve the hematoma** around the fracture guaranteeing rapid healing and good consolidation.
- 4 To permit **early mobilisation** helping to align the collagen fibres and quickly transform them into efficient elastic tendon fibres.

EQUIPMENT USED

TENOLIG consists of :

- a thread with a diameter of 0.85 mm and a length of 36 cm, crimped at its proximal end, onto which is mounted a 7 mm-wide harpoon, and crimped at its distal end by a triangular-tipped needle, 15 cm long, slightly curved at delivery and which can be adjusted during surgery according to a curve suitable for the type of rupture treated;
 - a perforated load for tightening;
 - an UHMW polyethylene disc, with a convex surface offering support that does not excessively compress the skin and a flat surface.
- 2 complete TENOLIG kits are required for a standard percutaneous tenosynthesis. Each pack contains 2 kits.



Product reference : 232 942
TENOLIG™ IMPLANT (batch of 2)
(FDA approved)

INDICATION

Surgical repair of Achilles tendon ruptures by the percutaneous route. It is preferable to conduct this procedure within **8 days** following rupture.

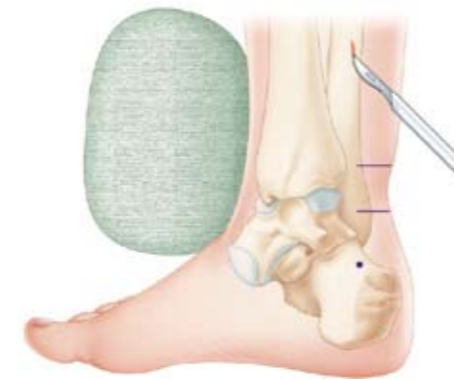
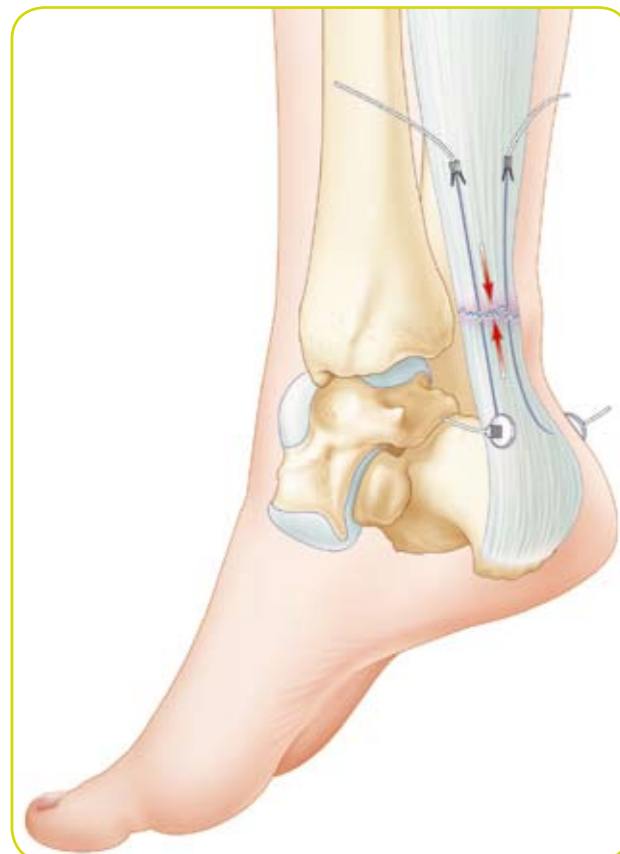
Fig. 1

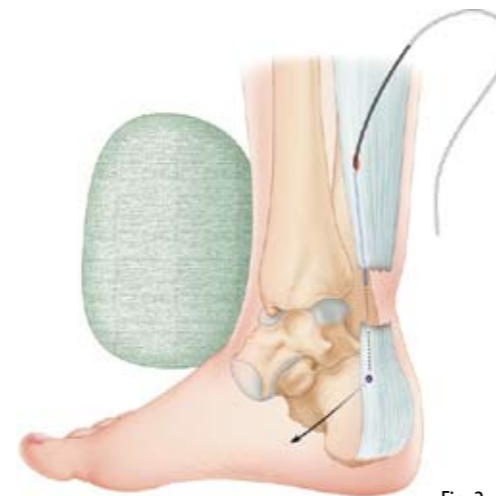


Fig. 2

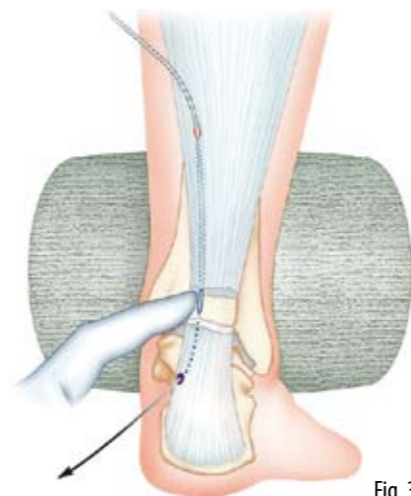


Fig. 3

SURGICAL TECHNIQUE

General, loco-regional or even local anaesthetic, depending on habits and context.

INSTALLATION

- Ventral decubitus position
- Preventive haemostasis by means of a tourniquet at the root of the thigh is not essential
- It is convenient to have a rounded pad with a sterile case to be placed on the front of the ankle during insertion of the TENOLIG and to be moved to the instep when tightening them.

DRAWING ON THE MARKS

Using a permanent marker, mark the following on the skin :

- The positions of the ruptured tendon ends which can always be felt very easily
- The proximal entry points, approximately 6 cm above the rupture zone on the postero-lateral surfaces of the tendon.
- The exit points on the postero-lateral surfaces of the tendon, opposite the retromalleolar spaces, 4 or 5 cm below the rupture.

These marks are essential, particularly for the exit points, which must be decided on in advance and complied with and not simply found randomly after the needle is inserted.

INSERTION OF THE 1ST TENOLIG™

One can decide to start with either TENOLIG - medial or lateral.

We will take the example of the medial TENOLIG.

- At the previously set entry point, a cutaneous hole of 5 to 6 mm (Fig. 1) is made using a scalpel. Using small tweezers (Halstead type), the cell tissue and subcutaneous fat is divided, pushing aside the sural nerve that could be pierced by the needle (Fig. 5).
- The needle is designed and curved on the basis of the proposed trajectory. Its plane is held by strong tweezers (a large needle-holder is ideal for the job). These are therefore positioned perpendicular to the curve of the needle, thus vertically, joint downwards and rings upwards.
- The needle must penetrate the tendon perpendicularly (Fig. 2) so that it is in the healthy zone. Then the trajectory is adjusted to catheterise the proximal fragment, tangentially, taking care not to push it too far in and risk damaging the internal tibial nerve.
- With the foot in a neutral position, thanks to the pad placed on the front of the ankle, the dehiscence is totally perceptible and one should feel the needle crossing it under one's finger (Fig. 3).
- It then penetrates the distal fragment and catheterises it. It should then be moved laterally. Place the foot in the equinus position and, thanks to the action exerted on the needle by the needle-holder, it should exit by the entry point **on the same side**, at the previously determined point (Fig. 4).
- The needle is pulled outwards until the harpoon is positioned at the level of the proximal entry point (Fig. 5). It is held by small tweezers, placed perpendicular to the tendon fibres and firmly fixed into the tendon, pulling the strap distally.

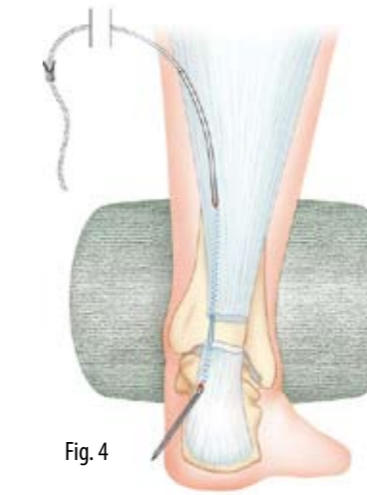

Fig. 4

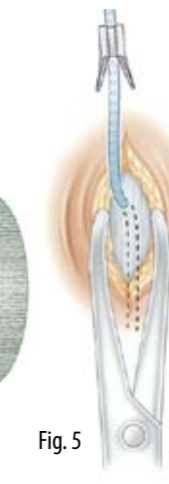

Fig. 5

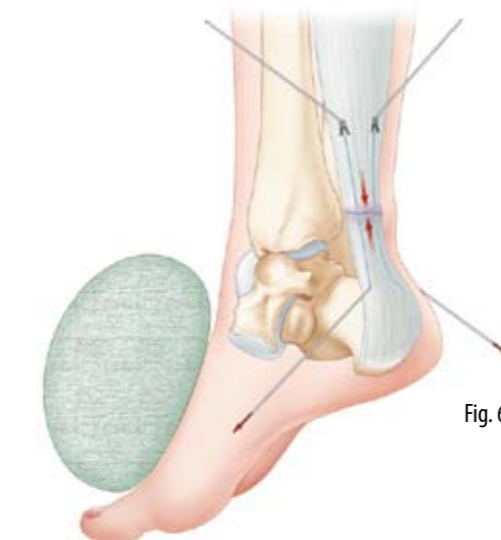


Fig. 6

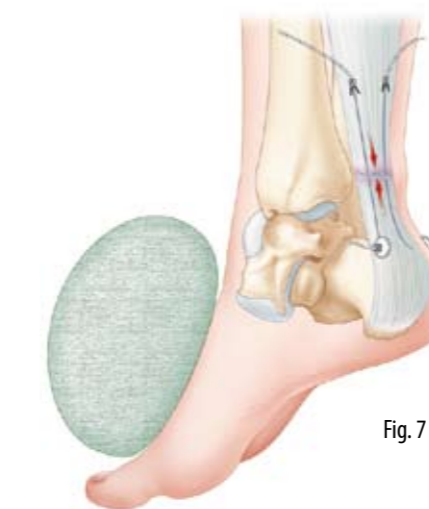


Fig. 7

INSERTION OF THE 2ND TENOLIG™

This is conducted in exactly the same conditions.

TIGHTENING

- The sterile pad is moved to the anterior surface of the instep to position the foot in a maximum equinus position.
 - The two straps are pulled tight simultaneously (Fig. 6). One must make sure that the harpoons are properly anchored. To make sure of this, their lengths from their distal exit points must be the same.
 - The plastic buttons are threaded on, convex surface against the skin. Then the weights are also threaded onto the straps and firmly tightened in contact with the buttons (Fig. 7).
 - It is then essential to assess the quality of the suture after having relaxed the tension on the straps :
 - by palpating the rupture zone,
 - by placing the leg vertically by flexing the knee to make sure that physiological equinus of the foot is indeed retained.
- This is the only criterion for the correct restoration of tendon tension. Otherwise, the weights must be removed and one must start again.

END OF SURGERY

- The distal ends of the straps are cut 2 to 3 cm from the weights.
- The proximal ends are left and the small cutaneous incisions are closed by a stitch or, for example, steristrips.
- A shaped compress is slipped under each plastic button to protect the skin. A simple dressing is then applied to cover the whole thing.
- A resin boot holding the foot in the equinus position is made, taking care not to compress the weights so that the skin is not damaged under the plastic buttons.

CONCLUSION

As with any "blind" technique, this is less easy than it appears. It must be scrupulously followed if one is to draw all the benefits of the technique. Any incorrect handling can lead to failure that is not the fault of the technique.